

See discussions, stats, and author profiles for this publication at: <https://www.researchgate.net/publication/290436400>

Autism Spectrum Disorders and Ehlers–Danlos Syndrome Hypermobility–Type : Similarities in clinical presentation.

Article · January 2016

CITATIONS

2

READS

1,223

4 authors, including:



Carolina Baeza-Velasco

Paris Descartes, CPSC

63 PUBLICATIONS 265 CITATIONS

[SEE PROFILE](#)



C. Hamonet

Université Paris-Est Créteil Val de Marne - Université Paris 12

286 PUBLICATIONS 318 CITATIONS

[SEE PROFILE](#)



Amaria Baghdadi

Centre Hospitalier Universitaire de Montpellier

75 PUBLICATIONS 817 CITATIONS

[SEE PROFILE](#)

Some of the authors of this publication are also working on these related projects:



Anxiety Joint Hypermobility View project



From observation to intervention: Identification of psychosocial determinants of pain and functional impairment, and development/evaluation of a psychosocial intervention for chronic pain in people with Joint Hypermobility Syndrome/Ehlers-Danlos syndrome hypermobility type (JHS/EDS-HT). [View project](#)

Autism Spectrum Disorders and Ehlers-Danlos Syndrome Hypermobility-Type : Similarities in clinical presentation

Trastornos del Espectro Autista y Síndrome de Ehlers-Danlos Hiper móvil: Similitudes en la presentación clínica

Carolina Baeza-Velasco C^a, Claude Hamonet^b, Amaria Baghdadli^c & Régine Brissot^d.

Recibido: 19/09/2015

Aceptado: 13/01/2016

Abstract

Autism Spectrum Disorder (ASD) is an etiologically and clinically heterogeneous group of neurodevelopmental conditions, characterized by impairments in communication, social interaction and restricted repetitive and stereotyped behaviors. Ehlers-Danlos Syndrome hypermobility-type (EDS-HT; also known as Joint Hypermobility Syndrome), is the most common hereditary disorder of the connective tissue. It is characterized by joint hypermobility and a wide range of articular and non-articular manifestations, including disturbances in different systems due to the widespread distribution of collagen in the body. The clinical presentations of ASD and EDS-HT share several similar features, and although literature that relates these two conditions is scarce, it suggests that a connective tissue disorder may contribute to autistic symptomatology. The present work reviews the similarities in the clinical presentation of both conditions. In addition, the case of a 12-year-old boy diagnosed with ASD in which autistic manifestations overlap and/or might be explained by the presence of EDS-HT is presented as illustration.

Key words: Autism spectrum disorder, Ehlers-Danlos syndrome, joint hypermobility syndrome.

^aAssistant Professor of Psychopathology. Institut de Psychologie, Université Paris Descartes, Sorbonne Paris Cité, France.

^bProfessor of Physical Medicine and Reahabilitation. Consultation Ehlers-Danlos, Centre de diagnostic et de thérapeutique, Hôtel-Dieu, Paris et Faculté de Médecine, Université Paris-Est-Créteil, France.

^cProfessor of Child Psychiatry. Centre de Ressources Autisme, CHU Montpellier et Laboratoire Epsilon, Université Montpellier 1, Montpellier, France.

^dProfessor of Physical Medicine and Reahabilitation. Clinique de Rééducation Fonctionnelle - Faculté de Médecine, Hôpital Pontchaillou, Rennes, France.

Address correspondence to: Carolina Baeza-Velasco, Institut de Psychologie, Université Paris Descartes, 71 Avenue Edouard Vaillant 92100 Boulogne-Billancourt cedex. (carolina.baeza-velasco@parisdescartes.fr)

Resumen

Los Trastornos del Espectro Autista (TEA) constituyen un grupo etiológica y clínicamente heterogéneo de condiciones del neurodesarrollo, caracterizadas por alteraciones en la comunicación, la interacción social y por la presencia de comportamientos repetitivos y estereotipados. El Síndrome de Ehlers-Danlos de tipo hipermóvil (SED-H), también conocido como Síndrome de Hiperlaxitud Articular, es la enfermedad hereditaria del tejido conectivo más frecuente. Se caracteriza por una hiperlaxitud articular y una amplia gama de manifestaciones articulares y no articulares, incluyendo alteraciones en diferentes sistemas debido a la amplia distribución del colágeno en el cuerpo. Las presentaciones clínicas de los TEA y el SED-H presentan varias características similares, y aunque la literatura que relaciona estas dos condiciones es escasa, sugiere que un trastorno del tejido conectivo puede contribuir a la sintomatología autista. El presente trabajo revisa las similitudes en la presentación clínica de ambas condiciones. Además, se presenta de manera ilustrativa el caso de un niño de 12 años de edad, diagnosticado con TEA, en la que las manifestaciones autistas se superponen y/o podrían explicarse por la presencia del SED-H.

Palabras clave: Trastornos del Espectro Autista, síndrome de Ehlers-Danlos, síndrome de hiperlaxitud articular.

INTRODUCCIÓN

Autism Spectrum Disorders (ASD) are a heterogeneous group of neurodevelopmental conditions characterized by impairments in communication, social interaction and restricted repetitive and stereotyped behaviors (American Psychiatric Association, 1994). ASD encompasses clinical presentations in which distinctions are made according to severity levels. Thus, categories such as pervasive developmental disorder not otherwise specified (PDD-NOS) and Asperger's syndrome, which were previously used to describe individuals who did not strictly fulfill autism criteria (Einsmajer et al., 1996), are now part of ASD since the arrival of the fifth edition of the Diagnostic Statistics Manual (DSM) (American Psychiatric Association, 2013).

The prevalence of ASD is 60 per 10,000 in developed countries (Newschaffer *et al.*, 2009). The etiology remains unknown and no biological tests exist for its diagnosis. People with ASD often display symptoms from other diagnostic categories (Hofvander *et al.*, 2009). Beyond the above mentioned core features, developmental (e.g.; intellectual disabilities), neurological disor-

ders (e.g.; epilepsy), psychiatric (e.g.; anxiety, mood disorders, ADHD) frequently co-occur in children with ASD and may have a significant impact on the identification, treatment needs, functional status, and progress of those affected (Gillbert & Billstedt, 2000).

EDS is a group of Heritable Disorders of the Connective Tissue (HDCT), which results from defective protein synthesis (Hakim & Sahota, 2006). There are several subtypes of EDS but common characteristics are generalized fragility of tissue, inherent tendency to mechanical tissue failure and joint hypermobility (JH), which is an increased range of motion of the joints, usually assessed with the Beighton score (Fig. 1) (Beighton, Salomon & Soskolne, 1973). The clinical presentation of EDS is extremely heterogeneous (De Wandele *et al.*, 2013; Ghibellini, Brancati & Castori, 2015). It includes disturbances in different systems due to the widespread distribution of collagen in the body. The most common subtype is the hypermobile type (EDS-HT) (also known as Joint Hypermobility Syndrome) (Castori, 2012). Although no real prevalence studies have been carried out, experts point out a high frequency of EDS-HT, especially in females. A pre-

valence of 45 % has been reported in rheumatologic patients in England (Grahame & Hakim, 2006), 39 % in Chile (Bravo & Wolff, 2006) and 1 million in France (Hamonet *et al.*, 2014). Nevertheless, EDS-HT is under-recognized (Castori, 2012), which delays diagnosis considerably.

manifestations. Considering the wide range of symptoms and the highly heritable nature of EDS-HT, a holistic approach of the examination and familiar anamnesis is needed.

ASD and EDS-HT are two conditions with a heterogenic clinical spectrum, sharing several similar

Beighton score	Left side	Right side
1. Passively touch the forearm with the thumb, while flexing the wrist	1	1
2. Bend the little finger back to $\geq 90^\circ$	1	1
3. Hyperextension of the elbows greater than or equal to 10°	1	1
4. Knees hyperextension greater than or equal to 10°	1	1
5. Touching the floor with the palms of the hands when reaching down without bending the knees	1	
Total	/9	

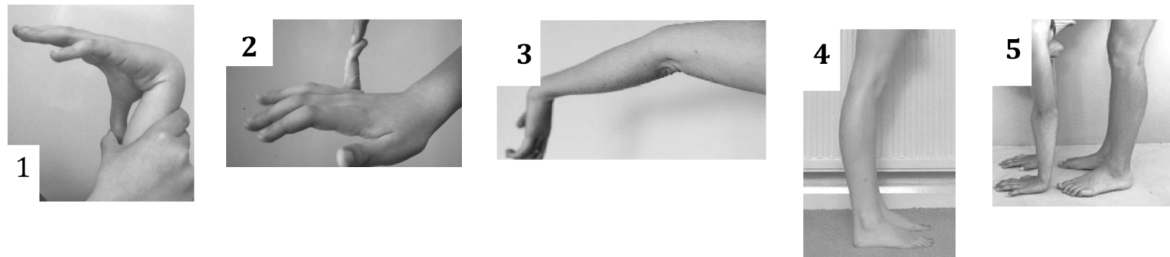


Figure 1
Beighton score (Beighton *et al.*, 1973)

The onset of symptoms typically occurs in infancy. Symptomatology tends to be milder in this period becoming more severe in adulthood (Castori, 2013). The diagnosis remains clinical in the absence of a biological confirmatory test. Two sets of diagnostic criteria are currently available: Villefranche (Table 1) (Beighton, De Paepe, Steinmann, Tsipouras & Wenstrup, 1998) and Brighton criteria (Table 2) (Grahame, Bird & Child, 2000). However, symptomatology of EDS-HT involves not only musculoskeletal complaints, but also many extra-articular manifestations not explored by these diagnostic tools (Bravo & Wolff, 2006; Castori, 2012; Ghibellini *et al.*, 2015). In this regard, a larger clinical spectrum of EDS-HT has been recently described (Colombi, Dordoni, Chiarelli & Ritelli, 2015; Hamonet *et al.*, 2014) (Table 3), including osteoarticular, muscular, mucocutaneous, gastrointestinal, cardiovascular, urogynaecological, ocular, dental and neuropsychiatric

phenotypical features as presented in table 4. However, there is a lack of awareness on this subject, as evidenced by the scarceness of references in the literature relating ASD and EDS. A recent study evidenced that children with ASD have greater mobility of joints than healthy controls, (Shetreat-Klein, Shinnar & Rapin, 2014). In addition, higher rates of JH and symptoms of autonomic dysfunction have been observed in adults with neurodevelopmental diagnoses, compared to psychiatric and healthy controls (Eccles *et al.*, 2014). Another study that assessed seven children with EDS found that five of them had severe behavioral problems and four had impaired social competences (Lumley, Jordan, Rubenstein, Tsipouras & Evans, 1994).

To our knowledge, there is no work that addresses the similarities in the clinical presentation of ASD and EDS-HT. The case presented below illustrates this purpose. Informed consent was obtained from parents of the patient.

Tabla 1
Clasificación de EDS syndromes (Beighton *et al.*, 1998)

New	Former	OMIM	Inheritance
Classical type	Gravis (EDS type I)	130000	AD
	Mitis (EDS type II)	130010	AD
Hypermobility type*	Hypermobility (EDS type III)	130020	AD
Vascular type	Arterial-ecchymotic I (EDS type IV)	130050	AD
		(225350)	
		(225360)	
Kyphoscoliosis	Ocular-scoliotic (EDS type VI)	225400	AR
		(229200)	
Arthrochalasia type	Arthrochalasia multiplex congenita (EDS types VIIA and VIIB)	130060	AD
Dermatosparaxis type	Human dermatosparaxis (EDS type VIIC)	225410	AR
Other forms	X-linked EDS (EDS type V)	305200	XL
	Periodontitis type (EDS type VIII)	130080	AD
	Fibronectin-deficient EDS (EDS type X)	225310	?
	Familial hypermobility syndrome (EDS type XI)	147900	AD
	Progeroid EDS	130070	?
	Unspecified forms	–	–

AD= autosomal dominant; AR= autosomal recessive; XL= X-linked.

*= Major criteria: Hyperextensible and/or smooth, velvety skin, generalized joint hypermobility; Minor criteria: Recurrent joint dislocation, chronic joint/limb pain, positive family history.

PATIENT PRESENTATION

We encountered a 12-year-old boy who was referred to the Department of Rehabilitation Medicine due to motor problems. The motor difficulties, which started in early childhood, included toe walking, poor stability in sitting position, poor tonic control and regulation, difficulties in object assembling, clumsiness with frequent falls and bumps, difficulties to dress himself and to learn to ride a bike.

Failure to respond to his name and random eye contact when he was a toddler were described in his medical record, as well as restricted interests and stereotypic behaviors, such as repeating sequences of films, frequent hand washing and chewing clothes. Preference for adults rather than children, social withdrawal, lack of empathy and initiative to share enjoyment, preference to stay in lying position at the park rather than to play, food se-

lectivity, sensory particularities, such as auditory and tactile hypersensitivities, altered temperature sensitivity and high anxious manifestations for small minimal injury, were also observed. There was no language delay.

Learning difficulties were detected at school, mainly in handwriting, attention and working memory. Due to his slowness to finish classwork, the teacher frequently asked him to complete work during the break. In addition, the patient was bullied at school, he had depressive symptoms (suicidal thoughts and self-injuries) and school phobia. These reasons motivated his parents to withdraw him from school and since he reached 10 years of age, the patient had been schooled at home.

Psychometric assessment revealed an intellectual quotient of 113 (normal-range) with a heterogeneous cognitive profile, characterized by performances in verbal comprehension and perceptively reasoning domains suggestive of high potential,

Table 2
Brighton Criteria (Grahame *et al.*, 2000)

Major Criteria

1. A Beighton score of 4/9 or greater (either currently or historically)
2. Arthralgia for longer than 3 months in 4 or more joints

Minor Criteria

1. A Beighton score of 1, 2 or 3/9 (0, 1, 2 or 3 if aged 50+)
2. Arthralgia (> 3 months) in one to three joints or back pain (> 3 months), spondylosis, spondylolysis/spondylolisthesis.
3. Dislocation/subluxation in more than one joint, or in one joint on more than one occasion.
4. Soft tissue rheumatism. > 3 lesions (e.g. epicondylitis, tenosynovitis, bursitis).
5. Marfanoid habitus (tall, slim, span/height ratio >1.03, upper: lower segment ratio less than 0.89, arachnodactyly [positive S Steinberg/wrist signs]).
6. Abnormal skin: striae, hyperextensibility, thin skin, papyraceous scarring.
7. Eye signs: drooping eyelids or myopia or antimongoloid slant.
8. Varicose veins or hernia or uterine/rectal prolapse.

The JHS is diagnosed in the presence two major criteria, or one major and two minor criteria, or four minor criteria. Two minor criteria will suffice where there is an unequivocally affected first-degree relative.

JHS is excluded by presence of Marfan or Ehlers-Danlos syndromes (other than the EDS Hypermobility type). Criteria Major 1 and Minor 1 are mutually exclusive as are Major 2 and Minor 2.

JHS: Joint Hypermobility Syndrome

and a poorer performance (although in the normal range) concerning processing speed and working memory. No standardized measures of autism severity, language ability or adaptive functioning were available. The several examinations he underwent, including neurological, psychiatric, psychological and psychomotor assessments, resulting in the diagnosis of PDD-NOS, dyspraxia and dysgraphia.

At the time of consultation in rehabilitation medicine, the main complaints were severe generalized pain (articular and muscular), chronic and visual fatigue, and gait problems. The clinical examination revealed a positive Beighton score for JH (8/9), history of recurrent sprains and blocks, dystonia, thin skin, abnormal scarring, easy bruising, cutaneous hyperesthesia, hypotonia, dysautonomia symptoms (excessive sweating, poor thermoregulation, unexplained fever episodes, dry eyes and mouth, dizziness), respiratory problems (dyspnea, respiratory blockages, recurrent affections of the upper airways), oral and gastrointes-

tinal problems (gastroesophageal reflux, dental problems, recurrent mouth ulcers), severe headaches, sensory problems (hyperacusis, tinnitus, transitory decrease of hearing, hyperaesthesia, hyperosmia, exophoria) and proprioceptive dysfunction (clumsiness, frequent trip and fall, difficulties in gripping and holding objects). Finally, the patient's father and brother had similar signs (although milder), while the patient's mother had been diagnosed with fibromyalgia.

This clinical picture suggests an EDS-HT according to Brighton (Grahame *et al.*, 2000) and Villefranche criteria (Beighton *et al.*, 1998), considering the other manifestations described in the EDS-HT spectrum (Colombi *et al.*, 2015; Hamonet *et al.*, 2014) (table 3), and in the absence of other HDCT (i.e. Marfan syndrome).

DISCUSSION

This case highlights the similarities in the clinical presentation of ASD and EDS-HT that

Table 3
Clinical Spectrum of EDS-HT (Colombe *et al.*, 2015; Hamonet *et al.*, 2014)

Osteoarticular	i.e. mild scoliosis, flat foot, lumbar hyperlordosis, joint hypermobility.
Muscular	i.e. hypotonia, fibromyalgia, recurrent myalgias and cramps, dystonia.
Mucocutaneous	i.e. mildly hyperextensible skin, velvety/silky/soft skin texture, striae rubrae and/or distensae in young age, small or post-surgical atrophic scars, Keratosis pilaris, hernias, light blue sclerae, gingival inflammation/recessions, hypoplastic lingual frenulum, easy bruising, resistance to local anaesthetic drugs.
Gastrointestinal	i.e. dysphagia, dysphonia, reflux gastroesophageal, gastritis, unexplained abdominal pain, food intolerances.
Cardiovascular	i.e. varicose veins, low progressive aortic root dilatation, pseudo-Raynaud's phenomenon, mitral valve prolapse.
Urogynaecological	i.e. dyspareunia, dysmenorrhea, urinary stress incontinence, meno/metrorrhagia.
Ocular	i.e. myopia, strabismus, palpebral ptosis.
Dental	i.e. dental neuralgia, gingivitis, temporo mandibular joint pain, dental pains to cold/ warm.
Neuropsychiatric	i.e. dysautonomia, clumsiness, proprioceptive dysfunction, paresthesia, headache, fatigue, sleep disturbances, cognitive impairment, anxiety, hyperaesthesia, hyperosmia, hyperacusis.

merit increased awareness among health professionals, especially pediatricians who are frequently the first contact for parents and the first stage in recognition (Plauché Johnson & Myers, 2007).

Certain characteristics often seen in ASD might be explained by an HDCT such as EDS-HT. The influence of motor and sensory capacity on behavior is undeniable. In this regard, EDS-HT characteristics such as motor difficulties, tissue fragility, sensory hypersensitivity, autonomic dysfunction and the consequences of proprioceptive impairments (impaired spatial localization, clumsiness, frequent falls, instability, abnormal posture, perception problems, bruxism, etc.) (Hamonet *et al.* 2014), may impact behavior in an "autistic" way. These patients frequently avoid noisy and hectic environments, and even physical contact. Clumsiness and slowness may cause rejection by others, especially at school (Baeza-Velasco, Bulbena, Pailhez *et al.*, in press). Isolation is frequently reported by patients with EDS-HT who often feel different and misunderstood (Myerson, 1994; Baeza-Velasco *et al.* 2011a). Rejection experiences and a preference for isolation or at least minimal social contact are also described

in people with ASD (White & Roberson-Nay, 2009). However in ASD these experiences are related to impairments in social-emotional reciprocity (deficits in back-and-forth flow of interactions).

Cognitive and learning problems such as dyspraxia and dysgraphia, are frequent in patients with EDS-HT (Ghibellini *et al.*, 2015) as in ASD (Mayes & Calhoun, 2007). Hand-wrist hypermobility along with proprioception troubles might help explain writing difficulties in EDS-HT. In this regard, therapeutic measures such as repetitive practice may be counterproductive in these patients, because it can cause pain and stiffness (Kirby & Davies, 2006).

In the present case, behaviors such as a preference to stay in a lying position rather than to play, might be related to chronic fatigue and/or dysautonomia, in which the transition from lying to standing position leads to a state of physical discomfort, with dizziness, fainting, visual disturbances, etc. Moreover, considering the history of transitory decrease of hearing, hyperacusis, difficulties in spatial localization and vision anomaly, it is not surprising to note a failure to respond to

Table 4
Common features in ASD and EDS-HT.

Features	Illustrative reference	
	in ASD	in EDS-HT
Attention deficit / hyperactivity	Mannion & Leader, 2013	De Wandele <i>et al.</i> , 2013
Atypical sense of self, alteration of the body schema	Lyons & Fitzgerald, 2013	Hamonet, 2012
Chronic gastrointestinal symptoms	McElhanon <i>et al.</i> , 2014	Colombi <i>et al.</i> , 2015
Clumsiness	Ming <i>et al.</i> , 2007	Colombi <i>et al.</i> , 2015
Difficulties in swallowing (dysphagia)	Betalli <i>et al.</i> , 2013	De Wandele <i>et al.</i> , 2013
Disorders of autonomic nervous system	Torres <i>et al.</i> , 2013	Bravo & Wolff, 2006
Food intolerances	McElhanon <i>et al.</i> , 2014	Colombi <i>et al.</i> 2015
Greater joint mobility, joint hypermobility	Shetreat-Klein <i>et al.</i> , 2014	Beighton <i>et al.</i> 1998
Hypotonia	Ming <i>et al.</i> , 2007	Colombi <i>et al.</i> , 2015
Impaired proprioception	Torres <i>et al.</i> , 2013	Hamonet <i>et al.</i> , 2014
Learning disabilities	Mayes & Calhoun, 2007	Adib <i>et al.</i> , 2005
Motor delay	Ming <i>et al.</i> , 2007	Beighton <i>et al.</i> , 1998
Motor impairment	Ming <i>et al.</i> , 2007	Hamonet <i>et al.</i> , 2014
Pathological anxiety	Simonoff <i>et al.</i> , 2008	Bulbena <i>et al.</i> , 1993
Sleeping problems	Mannion & Leader, 2013	De Wandele <i>et al.</i> , 2013
Social avoidance	Simonoff <i>et al.</i> , 2008	Baeza-Velasco <i>et al.</i> , 2011b
Toe-walking	Ming <i>et al.</i> , 2007	Castori <i>et al.</i> , 2012
Unusual sensory sensitivities	Talay-Ongan & Wood, 2000	Hamonet <i>et al.</i> , 2014

one's name and expressing random eye contact when toddler, as typically observed in ASD. According to Ghibellini *et al.* (2015), problems with the vestibular system in EDS-HT could impact visual competences including tracking issues and reading as well as auditory information processing.

Further, proprioceptive dysfunction and motor problems also influence the feelings and representations about one's own body. In this regard, an alteration in the perception of the body scheme has been described in both, EDS and autism (Hamonet, 2012; Lyons & Fitzgerald, 2013).

Considering overlapping clinical manifestations it is possible that some mild types of ASD represent an undiagnosed EDS-HT. In this sense, Pocinki (2013) stated that symptoms of autonomic dysfunction in EDS could be confounded with manifestation of psychiatric conditions. In this scenario, diagnostic accuracy is an important issue. In the presented case, the diagnostic of ASD was established without the use of evidence-based assessment tools. A battery to explore core

symptoms of ASD as well as additional domains such as intelligence, language, adaptive behavior, neuropsychological functions, comorbid psychiatric illnesses and contextual factors including family functioning and quality of life is recommended (Ozonoff, Goodlin-Jones & Solomon, 2005). For EDS-HT diagnosis, in addition to the exploration of known criteria of Villefranche and Brighton, a holistic approach and exploration of the broader clinical spectrum is necessary (table 3), as is also a familial anamnesis.

Moreover the co-occurrence of both conditions has been reported in six cases (Sieg, 1992; Tantam *et al.*, 1990; Takei *et al.*, 2011). According to Marino Lamari *et al.* (2015) EDS-HT features may worsen ASD symptoms. In this sense, Eccles *et al.* (2014), stated that the collagen altered condition and autonomic dysfunction might play a role in the generation and maintenance of psychopathology in neurodevelopmental disorders. Tantam, Evered and Hersov (1990) consider that an alteration of connective tissue might cause structural

abnormalities in the brain or a motor developmental delay with negative consequences in terms of non-verbal social ability and emotion expression.

From a clinical point of view, in more severe cases of ASD, the presence of a sign such as JH (sometimes recognizable through contortions and exacerbated flexibility in motor mannerisms) should not be trivialized. Especially since recent research shows a higher rate of JH in people with developmental disorders compared to controls (Eccles *et al.* 2014; Shetreat-Klein *et al.*, 2014). JH, as well as antecedents of JH and/or chronic pain in relatives, should alert and warrant a thorough evaluation in order to screen for an HDCT, and in consequence, a tendency to suffer from pain, which is particularly relevant if we consider the communication impairments in this population. The appearance or accentuation of aberrant behaviors or behavioral changes in this context might be a manifestation of pain. In this regard, it has been shown that children with ASD react with self-injurious behaviors immediately after a painful experience (Tordjman *et al.*, 1999).

It is important to disseminate this knowledge among child health professionals, in order to improve diagnostic accuracy, develop appropriate treatment and school facilities to allow the integration of these children. Future research is needed to deepen the knowledge of the etiology of these two disorders both exhibiting a strong genetic component.

Acknowledgements: The authors wish to thank Dr. Isabelle Brock and the patient in the study and his parents for sharing their experiences.

Funding Source: No funding was secured for this study.

Conflict of Interest: The authors have no conflicts of interest to disclose.

Financial Disclosure: The remaining authors have no financial relationships relevant to this article to disclose.

REFERENCES

1. **Adib, N., Davies, R., Grahame, R., Woo, P., Murray, KJ.** (2005). Joint hypermobility syndrome in childhood. A not so benign multisystem disorder? *Rheumatology (Oxford)*, 44: 744-750.
2. **American Psychiatric Association.** (1994). *Diagnostic and Statistical Manual of Mental Disorders*, 4th edn. Washington, DC: American Psychiatric Association.
3. **American Psychiatric Association.** (2013). *Diagnostic and statistical manual of mental disorders (5th ed.)*. Arlington, VA: American Psychiatric Publishing.
4. **Baeza-Velasco, C., Bulbena, A., Pailhez, G., Bourdon, C., De Jouvencel, M.** (in press) Syndrome d'Ehlers-Danlos Hypermobile : Considérations psychologiques. *Journal de Réadaptation Médicale*. Doi: 10.1016/j.jrm.2015.09.004.
5. **Baeza-Velasco, C., Gély-Nargeot, MC., Bulbena, A., & Bravo, JF.** (2011a). Joint hypermobility syndrome: problems that require psychological intervention. *Rheumatology International*, 31: 1131-1136. Doi: 10.1007/s00296-011-1839-5.
6. **Baeza-Velasco, C., Gély-Nargeot, MC., Bulbena, A., Fénétrier, C., & Bravo, JF.** (2011b). Association between psychopathological factors and joint hypermobility syndrome in a group of undergraduates from a French university. *International Journal of Psychiatry in Medicine*, 41: 187-201.
7. **Beighton, P., De Paepe, A., Steinmann, B., Tsipouras, P., & Wenstrup, RJ.** (1998). Ehlers-Danlos syndromes: revised nosology, Villefranche, 1997. Ehlers-Danlos National Foundation (USA) and Ehlers-Danlos Support Group (UK), *American Journal of Medical Genetics*, 77: 31-37.
8. **Beighton, P., Solomon, L., & Soskolne, C.** (1973). Articular mobility in an African population. *Annals of the Rheumatic Diseases*, 32: 413-418.
9. **Betalli, P., Carretto, E., Cananzi, M., Zanatta, L., Salvador, R., Galeazzi, F., Guariso, G., Gamba, P., & Costantini, M.** (2013). Autism and esophageal achalasia in childhood: a possible correlation? Report on three cases. *Diseases of the Esophagus*, 26: 237-240. Doi: 10.1111/j.1442-2050.2012.01358.x.
10. **Bravo, J., & Wolff, C.** (2006). Clinical study of hereditary disorders of connective tissues in a Chilean population. *Joint Hypermobility Syndrome and vascular Ehlers-Danlos syndrome. Arthritis and Rheumatism*, 54: 515-523.
11. **Bulbena, A., Duro, J., Porta, M., Martin-Santos, R., Mateo, A., Molina, L., Vallescar, R., & Vallejo, J.** (1993). Anxiety disorder?

- der in the joint hypermobility syndrome. *Psychiatry Research*, 43: 59-68.
12. **Castori, M.** (2012). Ehlers-Danlos Syndrome, Hypermobility Type: An Underdiagnosed Hereditary Connective Tissue Disorder with Mucocutaneous, Articular, and Systemic Manifestations. *Dermatology*, ID 751768. Doi: 10.5402/2012/751768.
 13. **Castori, M.** (2013). Joint hypermobility syndrome (a.k.a. syndrome hypermobility type): An update critique. *Giornale Italiano di Dermatologia et Venereologia*, 148: 13-36.
 14. **Colombi, M., Dordoni, C., Chiarelli, N., & Ritelli, M.** (2015). Differential Diagnosis and Diagnostic Flow Chart of Joint Hypermobility Syndrome/Ehlers–Danlos Syndrome Hypermobility Type Compared to Other Heritable Connective Tissue Disorders. *American Journal of Medical Genetics Part C*, 169: 6-22. Doi: 10.1002/ajmg.c.31429.
 15. **De Wandele, I., Rombaut, I., Malfait, F., De Backer, T., De Paepe, A., & Calders, P.** (2013). Clinical heterogeneity in patients with the hypermobility type of Ehlers-Danlos Syndrome. *Research in Developmental Disabilities*, 34: 873-881. Doi: 10.1016/j.ridd.2012.11.018.
 16. **Eccles, JA., Lodice, V., Dowell, NG., Owens, A., Hughes, L., Skipper, S., Lycette, Y., Humphries, K., Harrison, NA., Athias, CJ., & Critchley, HD.** (2014). Joint hypermobility and autonomic hyperactivity: relevance to neurodevelopmental disorders. *Journal of Neurology, Neurosurgery, and Psychiatry*, 85, e3. Doi: 10.1136/jnnp-2014-308883.9.
 17. **Einsenmajer, R., Prior, M., Leekam, S., Wing, L., Gould, J., Welham, M., & Ong, B.** (1996) Comparison of clinical symptoms in autism and Asperger's disorder. *Journal of the American Academy of Child and Adolescent Psychiatry*, 35: 1523-1531. Doi: 10.1097/00004583-199611000-00022.
 18. **Ghibellini, G., Brancati, F., & Castori, M.** (2015). Neurodevelopmental attributes of joint hypermobility syndrome/Ehlers–Danlos syndrome, hypermobility type: Update and perspectives. *American Journal of Medical Genetics Part C*, 169: 107-116. Doi: 10.1002/ajmg.c.31424.
 19. **Gillberg C, Billstedt E.** (2000). Autism and Asperger syndrome: coexistence with other clinical disorders. *Acta Psychiatrica Scandinavica*, 102: 321-330.
 20. **Grahame, R., Bird, HA, & Child, A.** (2000). The revised (Brighton 1998) criteria for the diagnosis of benign joint hypermobility syndrome (BJHS). *Journal of Rheumatology*, 27: 1777–9.
 21. **Grahame, R., & Hakim, A.** (2006). Joint hypermobility syndrome is highly prevalent in general rheumatology clinics, its occurrence and clinical presentation being gender, age and race-related. *Annals of Rheumatic Diseases*, 65: 263.
 22. **Hakim, A., & Sahota, A.** (2006). Joint hypermobility and skin elasticity: the hereditary disorders of connective tissue. *Clinics in Dermatology*, 24: 521-533.
 23. **Hamonet, C., Gompel, A., Raffray, Y., Zeitoun, JD., Delarue, M., Vlamynck, E., Haidar, R., & Mazaltarine, G.** (2014). Multiple pains in Ehlers-Danlos syndrome. Description and proposal of a therapy protocol. *Douleurs*, 15: 264-277. Doi: 10.1016/j.douleur.2014.09.003.
 24. **Hamonet, C.** (2012). Le Syndrome d'Ehlers-Danlos, de l'errance au diagnostic. *Eloge de la clinique. L'Internat de Paris*, 66: 1-7.
 25. **Hofvander, B., Delorme, R., Chaste, P., Nydén, A., Wentz, E., Ståhlberg, O., Herbrecht, E., Stopin, A., Anckarsäter, H., Gillberg, C., Råstam, M., & Leboyer, M.** (2009). Psychiatric and psychosocial problems in adults with normal-intelligence autism spectrum disorders. *BMC Psychiatry*, 10, 9: 35. Doi: 10.1186/1471-244X-9-35.
 26. **Kirby, A., & Davies, R.** (2006). Developmental coordination disorder and joint hypermobility syndrome - overlapping disorders? Implications for research and clinical practice. *Child: Care, Health, and Development*, 32: 513-519.
 27. **Lumley, MA., Jordan, M., Rubenstein, R., & Tsipouras, P.** (1994). Evans MI. Psychosocial functioning in the Ehlers–Danlos syndrome. *American Journal of Medical Genetics*, 53: 149-52.
 28. **Lyons, V., & Fitzgerald, M.** (2013). Atypical Sense of Self in Autism Spectrum Disorders: A Neuro-Cognitive Perspective. In *Recent Advances in Autism Spectrum Disorders - Volume I*, Fitzgerald M. (Ed.). InTech. Doi: 10.5772/53680.
 29. **Mannion, A., & Leader, G.** (2013). Comorbidity in autism spectrum disorders: A literature review. *Research in Autism Spectrum Disorders*, 7: 1595-1616. Doi: 10.1016/j.rasd.2013.09.006.
 30. **Marino Lamari, N., Marino Lamari, M., Carvalho Marino, B., Peres de Medeiros, M.** (2015, August). Síndrome de Ehlers-Danlos tipo hiper mobilidade no agravado dos transtornos do espectro do autismo: relato de caso. Poster session presented at the II International Congress on Hypermobility, Ehlers–Danlos Syndrome and Pain. Sao Jose do Rio Preto, Brazil.

31. **Mayes, SD., & Calhoun, SL.** (2007). Learning, Attention, Writing, and Processing Speed in Typical Children and Children with ADHD, Autism, Anxiety, Depression, and Oppositional-Defiant Disorder. *Child Neuropsychology*, 13: 469-93.
32. **McElhanon, BO., McCracken, C., Karpen, S., & Sharp, WG.** (2014). Gastrointestinal symptoms in autism spectrum disorders: A meta-analysis. *Pediatrics*, 133: 872-883. Doi:10.1542/peds.2013-3995.
33. **Ming, X., Brimacombe, M., & Wagner, C.** (2007). Prevalence of motor impairment in autism spectrum disorders. *Brain & Development*, 29: 565-570.
34. **Myerson, L.** (1994). Clinical versus empathetic encounters with Ehlers-Danlos Syndrome. *Anthropology of Work Review*. 15: 22-27. Doi: 10.1525/awr.1994.15.2-3.22.
35. **Newschaffer, CG., Croen, LA., Daniels, J., Giarelli, E., Grether, JK., Levy, SE., Mandell, DS., Miller, LA., Pinto-Martin, J., Reaven, J., Reynolds, AM., Rice, CE., Schendel, D. & Windham, GC.** (2007). The Epidemiology of Autism Spectrum Disorders. *Annual Review of Public Health*, 28: 235-258.
36. **Ozonoff, S., Goodlin-Jones, BL., Solomon M.** Evidence-Based Assessment of Autism Spectrum Disorders in Children and Adolescents. *Journal of Clinical Child & Adolescent Psychology* 2005, 34: 523-540. Doi:10.1207/s15374424jccp3403_8.
37. **Plauché Johnson, C., & Myers, SM.** (2007) Identification and evaluation of children with autism spectrum disorders. *Pediatrics* 120: 1183-1215. Doi: 10.1542/peds.2007-2361.
38. **Pocinki AG.** Pseudopsychiatric symptoms in EDS. Paper presented at: The Ehlers-Danlos National Learning Conference; August 2-3, 2013; Providence, RI.
39. **Shetreat-Klein, M., Shinnar, S., & Rapin, I.** (2014). Abnormalities of joint mobility and gait in children with autism spectrum disorders. *Brain & Development*, 36: 91-6. Doi: 10.1016/j.braindev.2012.02.005.
40. **Sieg, KG.** (1992). Autism and Ehlers Danlos syndrome. *Journal of the American Academy of Child & Adolescent Psychiatry*, 31: 173.
41. **Simonoff, E., Pickles, A., Charman, T., Chandler, S., Loucas, T., & Baird, G.** (2008). Psychiatric Disorders in Children With Autism Spectrum Disorders: Prevalence, Comorbidity, and Associated Factors in a Population-Derived Sample. *Journal of the American Academy of Child and Adolescent Psychiatry*, 47: 921-929. Doi:10.1097/CHI.0b013e318179964f.
42. **Takei, A., Mera, K., Sato, Y., Haraoka, Y.** (2011). High-functioning autistic disorder with Ehlers-Danlos syndrome. *Psychiatry and Clinical Neurosciences*, 65: 605-6. Doi: 10.1111/j.1440-1819.2011.02262.x.
43. **Talay-Ongan, A., & Wood, K.** (2000). Unusual sensory-sensitivities in autism: A possible crossroads. *International Journal of Disability, Development and Education*, 47: 201-212. Doi: 10.1080/713671112.
44. **Tantam, D., Evered, C., & Hersov, L.** (1990). Asperger's syndrome and ligamentous laxity. *Journal of the American Academy of Child and Adolescent Psychiatry*, 29: 892-6.
45. **Tordjman, S., Antoine, C., Cohen, DJ., Gauthier-Picard, A., Carlier, M., Roubertoux, P., & Ferrari, P.** (1999). Study of the relationships between self-injurious behavior and pain reactivity in infantile autism. *L'Encephale*, 25: 122-34.
46. **Torres, EB., Brincker, M., Isenhower, RW., Yanovich, P., Stigler, KA., Numberger, JI., Metaxas, DN. & José, JV.** (2013). Autism: the micro-movement perspective. *Frontiers in Integrative Neuroscience*, 7:32. Doi: 10.3389/fnint.2013.00032.
47. **White, SW., Roberson-Nay, R.** (2009) Anxiety, social deficits, and loneliness in youth with autism spectrum disorders. *Journal of Autism and Developmental Disorders*, 39: 1006-1013. Doi: 10.1007/s10803-009-0713-8.